

# The Effect of Ranitidine Administration Time to Axon Degeneration due to Optic Nerve Neuropathy

Galih Ricci Muchamad<sup>1</sup>, Dwi Pudjonarko<sup>1,2</sup>

<sup>1</sup>Department of Medicine, Faculty of Medicine, Diponegoro University, Semarang, Indonesia

<sup>2</sup>Department of Neurology, Faculty of Medicine, Diponegoro University, Semarang, Indonesia

Correspondence to Galih Ricci Muchamad, Email [muchamadricci@gmail.com](mailto:muchamadricci@gmail.com), Cell +6285786406428

## ABSTRACT

**Background:** Formic acid is the end product of methanol metabolism that can damage the axons of the optic nerve. Previous studies have suggested that, besides ethanol and fomepizole, ranitidine can inhibit the formation of this formic acid. However, the timing of administration of ranitidine in acute methanol intoxication is unknown. The study aim to determine the effect of ranitidine administration time to degeneration of axon optic nerve in the incidence of acute methanol intoxication.

**Method:** The study used 4 groups with 6 rats in each group. Two treatment groups and the positive control group were given methanol 14 g/kg BW, the first treatment group was given ranitidine 30 mg/kgBW right after administration of methanol and second group 30 minutes after methanol administration. Meanwhile, the negative control group was given oral aquadest, then rats were terminated after 8 hours

**Results:** Histological examination of optic nerve with H&E showed the administration of ranitidine right after methanol administration can inhibit optic nerve degeneration significantly ( $p < 0.05$ ). Meanwhile, the administration of ranitidine after 30 minutes had not been able to inhibit optic nerve degeneration significantly ( $p > 0.05$ )

**Conclusion:** Ranitidine administration right after acute methanol intoxication can prevent optic nerve degeneration significantly. Further research is needed to investigate the effect of ranitidine dose on the degeneration rate of the axons of the optic nerve

**Keyword:** axon degeneration, methanol, neuropathy, optic nerve, ranitidine

---

## INTRODUCTION

Methanol is a substance that is easily absorbed by the body, either ingestion, inhalation, or direct contact. Methanol metabolism results in the form of formic acid which is very toxic<sup>1</sup>. After the absorption process, methanol will be distributed rapidly and reach peak levels in the blood within 30-90 minutes after exposure<sup>2</sup>. Methanol is then taken to the liver which is the primary metabolic site of methanol. When undergoing primary metabolism, methanol will be metabolized into formaldehyde with alcohol dehydrogenase (ADH) enzyme, then formaldehyde will be metabolized rapidly into formic acid with formaldehyde dehydrogenase enzyme. The oxidation process that produces formic acid takes place more rapidly than the change of methanol to formaldehyde so that only a small amount of formaldehyde accumulates in the serum<sup>3</sup>. The half-life of formaldehyde is about 1-2 minutes<sup>2</sup>.

In addition, formic acid can penetrate the blood brain barrier that can cause toxicity of the central nervous system<sup>4</sup>. One of the toxicity is the toxicity of the optic nerve which ultimately causes symptoms of visual disturbance one of them in the form of optic nerve neuropathy that can affect on the occurrence of axon degeneration<sup>5</sup>.

The acidosis metabolic incidence in methanol intoxication can be minimized by the addition of bicarbonate. In addition, antidotes are also often used to relieve the reaction of methanol intoxication. Commonly used antidotes include ethanol or fomepizole, which works by inhibiting the action of alcohol dehydrogenase enzymes so that methanol metabolism into formic acid can be reduced.<sup>6,7</sup> The administration of the antidote should be carried out immediately after signs of methanol intoxication are known<sup>8</sup>.

In addition to the above-mentioned drugs, it has recently been found that ranitidine, initially used only as adjunctive therapy, has the effect of decreasing the formic acid content considerably to the value of formic acid under normal conditions.<sup>9</sup> Ranitidine aside from being anti-histamine (H<sub>2</sub>), has other pharmacodynamics in the human body as an inhibitor of the cytochrome P450 enzyme and as an inhibitor of the gastric and hepatic alcohol dehydrogenase (ADH) enzyme.<sup>10</sup> The ADH enzymes work in methanol metabolism process into formaldehyde. Due to the decrease in production of formaldehyde, the production of formic acid can be decreased. The timing of ranitidine is important because, according to the American Academy of Clinical Toxicology, ranitidine should be administered as soon as possible based on anamnesis and physical examination while awaiting laboratory results. This affects the metabolic rate of acidosis and the degeneration rate of axons in the optic nerve<sup>11,8</sup>.

Based on this background, a study was conducted to assess the effect of ranitidine administration time to axon degeneration due to optic nerve neuropathy by using Wistar rat research subjects with acute methanol intoxication.

## METHOD

This experimental study was carried out in Experimental Research Laboratory (Animal House) Faculty of Medicine, Diponegoro University and Histopathology Laboratory Faculty of Medicine, Diponegoro University. The experimental protocol was approved by the Commission of Health Research Ethics Faculty of Medicine, Diponegoro University and Central General Hospital Dr. Kariadi, Semarang, Indonesia.

**Sampling technique:** A total of 24 samples of male Wistar rats that had met the inclusion criteria were taken. The rats were divided into 4 groups with each group of 6 rats with allocation random sampling.

**Grouping:**

- Group I Negative Control Group (K) The first group was a negative control group (K), given only oral aquadest.
- Group II Positive Control Group (P1), given methanol orally 14 g/kg BW.
- Group III Treatment Group 1 (P2), given methanol and followed by ranitidine 30 mg/kgBW right after the administration of methanol.
- Group IV Treatment Group 2 (P3), given methanol and followed by ranitidine 30 minutes after administration of methanol.

**Histopathological preparation:** The rats were terminated after 8 hours. The optic nerve was dissected from the eyeball at a distance of one millimeter behind the sclera and was attempted to obtain a length of optic nerve specimen along a minimum of 2 millimeters. Histological preparations were then made using H&E staining.

**Microscopic features:** The optic nerve is deemed to degenerate when axon alteration, axon swelling or axon shrinkage, axon structural disorder or axon loss, ovoid formation (axon debris) is present. Observations were made on four visual fields each specimen with a magnification of 400x.

**Statistical analysis:** Data was collected and analyzed using SPSS version 20. Normality test of data distribution is done by Saphiro-wilk test because the sample amount is less than 50 or small sample. From the statistical calculation obtained p value>0.05 it shows that normal distributed data. In this study used more than 2 groups with 1 treatment, therefore after the results obtained that the data is normally distributed, then tested the variant with Levene's test. The result of variance test yield p value>0.05 then the variant is the same, so the hypothesis test is One Way Anova and Post Hoc Bonferroni.

**RESULTS**

Table 1: Comparison of Degeneration Degree of Axons between Research Groups

Variable	Group	N	Mean ± SD
DDAT	K	6	10.50 ± 4.806
	P1	6	18.67 ± 4.502
	P2	6	13.67 ± 2.338
	P3	6	16.83 ± 3.312

P value 0.008, F n5.19

One Way Anova Test, p: value of significance  
Based on the data in table 1 it is known that all research groups are normally distributed and homogeneous, while for the F value arithmetic contained in the table shows that the null hypothesis is not proven, which means there is a relationship between independent variables and dependent variables.

Table 2: Comparative Analysis of Degeneration Degree of Axons among Research Groups

Group	Average difference	CI95%		P value
		Minimal	Maximal	
K vs P1	8.167	-12.82	-3.51	0.002
K vs P2	3.167	-7.82	1.49	0.171
K vs P3	6.333	-10.99	-1.68	0.010
P1 vs P2	5.000	0.34	9.66	0.037
P1 vs P3	1.833	-2.82	6.49	0.421

Post Hoc Bonferroni Test p: significant value (significant when p<0.05)

Table 2 shows a significant difference between negative control group (K) and positive control group (P1), negative control group (K) with treatment 2 (P3), and positive control group (P1) with treatment group 1 (P2). However, there was no significant difference between negative control group (K) and treatment group 1 (P2) and positive control group (P1) with treatment group 2 (P3).

In the histopathologic view of the optical nerve of the Wistar rat the negative control group (**Figure 1**) obtained a normal axon image (black cell nucleus, round cell shape or kite-like) that dominates both in the field of view with 100x and 400x magnifications. This shows the degree of degeneration of the optic nerve axons in the negative control group is minimum.

In the histopathologic view of the optical nerve of the positive controlled Wistar rats (**Figure 2**), it is found that there are images of degenerated axons (cellular changes, cytoplasmic swelling, axon loss, ovoid / debris axon formation) dominating both in the field of view with 100x and 400x magnifications compared with normal axon. This indicates that the degeneration rate of axon will increase with methanol administration in the positive control group.

In the histopathology of the optical nerve of the treatment group 1 (**Figure 3**), ie the Wistar rats group given ranitidine 30 mg/kgBW right after methanol administration, it was found that there was a normal axon image dominating both in the field of view with 100x and 400x magnification compared to the positive control group. This suggests ranitidine 30 mg/kgBW right after administration of methanol can reduce axon degeneration rates due to methanol intoxication. Normal Axon description in treatment group 1 was better than description in treatment group 2. It can be concluded that administering ranitidine 30 mg/kgBW right after methanol administration was effective in decreasing degeneration rate of axons of optic nerve.

In the histopathology of the optical nerve of the wistar rat of the treatment group 2 (Figure 4), ie the wistar rats group given ranitidine 30 mg / kgBB 30 min after methanol administration, it was found that there was a normal axon image dominating both in the field of view with 100x and 400x magnification compared to the positive control group . This suggests ranitidine 30 mg / kgBB 30 minutes after methanol administration can decrease axon degeneration rate due to methanol intoxication. However, the normal axon image in the treatment arm 2 was less than the treatment group 1. This concluded that administering ranitidine 30 mg / kgBW right after methanol administration was most effective in reducing the degeneration rate of the axons of the optic nerve.

Fig.1: (A) Magnification 100 x and Figure (B) 400 x (HE). The black arrows show the image of a normal axon (black cell nucleus, round cell shape, or kite-like) and red arrows indicate a degenerated axon

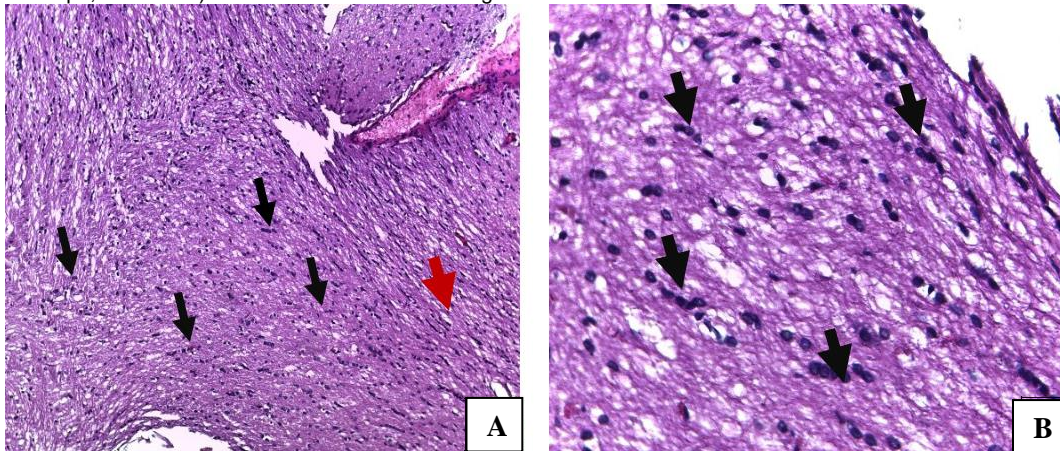


Fig. 2: Histopathological Image of Wistar Rat Optical Nerve of Positive Control Group. Figure (A) Magnification 100 x and Figure (B) 400 x (HE). The black arrows show the image of a normal axon (black cell nucleus, round cell shape, or kite-like) and red arrows indicate a degenerated axon

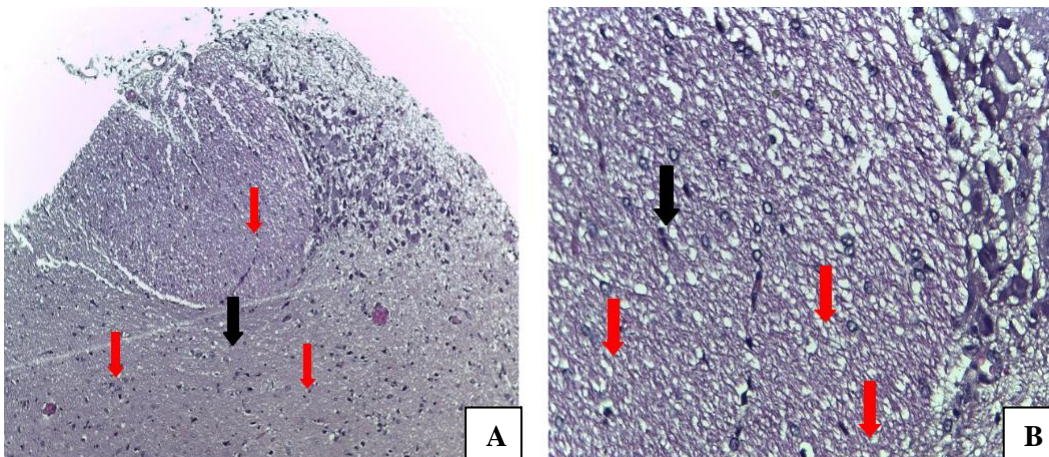


Fig. 3: Histopathological Image of Wistar Rat Optical Nerve of Treatment Group 1. Figure (A) Magnification 100 x and Figure (B) 400 x (HE). The black arrows show the image of a normal axon (black cell nucleus, round cell shape, or kite-like) and red arrows indicate a degenerated axon

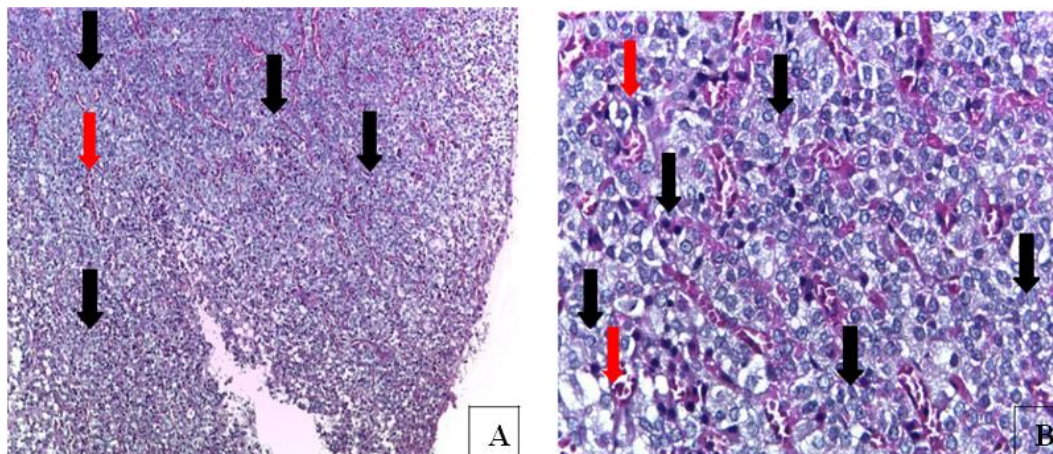
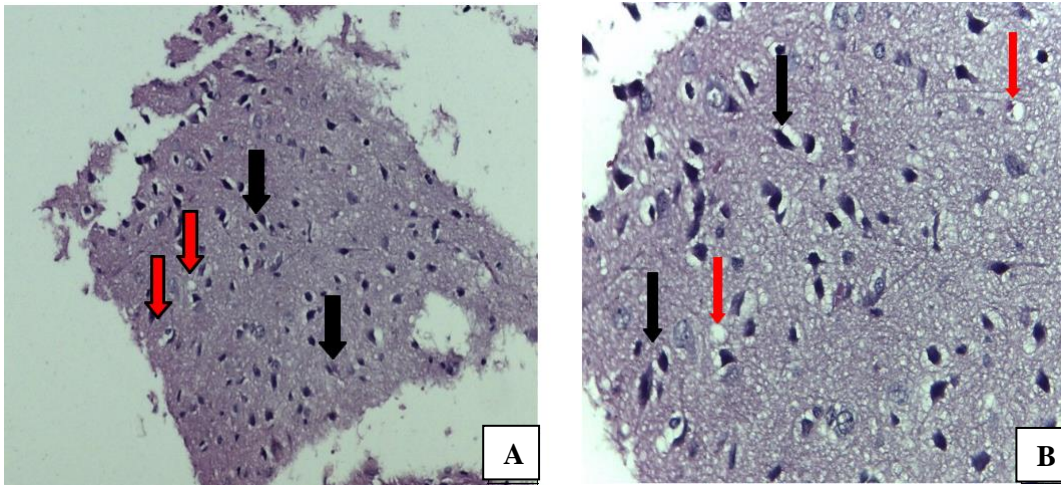


Fig. 4: Histopathological Image of Wistar Rat Optical Nerve of Treatment Group 2. Figure (A) Magnification 100 x and Figure (B) 400 x (HE). The black arrows show the image of a normal axon (black cell nucleus, round cell shape, or kite-like) and red arrows indicate a degenerated axon



## DISCUSSION

Methanol is a simple, readily absorbable alcoholic compound and its metabolism is toxic to the human body.<sup>12</sup> Peak levels of methanol in plasma can be achieved after 30-90 minutes after exposure.<sup>2</sup> If methanol is consumed in excess, the concentration of methanol in the blood increases so that symptoms methanol toxicity<sup>13</sup>. One of them is an eye with symptoms such as photophobia, blurred vision, to complete blindness due to high methanol exposure<sup>28</sup>.

Toxicity to the central nervous system is caused by free formic acid that can penetrate the blood-brain barrier (BBB). Formic acid is produced from methanol metabolism by using formaldehyde dehydrogenase enzyme in liver and gastric lasting for 1-2 minutes. However, the metabolism of formic acid to carbon dioxide and water takes a long time. This results in the accumulation of formic acid in the body and causes metabolic acidosis. In addition, formic acid is also an inhibitor of the cytochrome-c oxidase enzyme resulting in disruption of oxygenation in the tissues. The effect of lack of tissue oxygenation is a decrease in cell-neutralizing activity that causes cell swelling, dilatation of the endoplasmic reticulum, and calcium pump failure resulting in excessive calcium ion influx and resulting in irreversible deterioration of mitochondria and lysosome membranes. Mitochondrial damage causes ATP production diminishes, if it occurs in the optic nerve it will lead to the occurrence of the axoplasm static flow and cause edema of the axon, edema of the optic disk, to the loss of visual function due to a degenerated axon<sup>14</sup>.

Ranitidine commonly used as a H<sub>2</sub> histamine receptor antagonist, also has a pharmacodynamic effect as an enzyme inhibitor of alcohol dehydrogenase, thereby lowering methanol metabolism rate to formaldehyde. This results in free formic acid production being decreased and the degeneration rate of axons in the optic nerve may be inhibited. The timing of ranitidine is important because, according to the American Academy of Clinical Toxicology, ranitidine should be administered as soon as possible based on anamnesis and physical examination while

awaiting laboratory results. This affects the metabolic rate of acidosis and degeneration rate of axons in the optic nerve<sup>8,10,11</sup>. Therefore, administration of ranitidine is given right after and 30 minutes after methanol administration so that ranitidine is expected to inhibit methanol metabolism to formic acid. Meanwhile, the termination process was performed 8 hours after methanol intoxication so that toxic effects were expected to be seen in the positive control group, treatment group 1, and treatment group 2.

Based on the results of the research and statistical calculations, there was a significant difference between the positive control group (rats given treatment in the form of acute methanol intoxication) and treatment group 1 (rats given treatment in the form of acute methanol intoxication along with ranitidine administration right after methanol administration).

This is supported by the study of Hietala J et al., the degeneration of axon is highly dependent on the rate of formaldehyde metabolism to formic acid<sup>15</sup>. In the previous study showed that the rate of formaldehyde oxidation to formic acid in rats was 78 mg/kg/hr, while in humans 40 mg/kg/hr. The high oxidation rate in these rats caused the accumulation of formic acid in rats higher than humans. Therefore, the speed of administration of antidote greatly affect the level of metabolic acidosis and degeneration of axons due to acute methanol intoxication.

While for the negative control group (rats that were not given any treatment) when compared with the treatment group and the positive control group in the statistical calculation obtained significant results, so that there is a significant difference. This suggests that the administration of acute methanol intoxication may lead to degeneration of axons in the optic nerve. These results are supported by studies suggesting that methanol intoxication can cause ocular toxicity due to cytochrome-c oxidase inhibition in the optic nerve due to accumulation of formic acid. Formic acid is produced from formaldehyde metabolism within 1-2 minutes, but the conversion of formic acid to the final product of carbon dioxide and water takes

a long time. This results in an increase in optic nerve damage due to acute methanol intoxication.

## CONCLUSION

In the first treatment group the group given methanol toxic dose of 14 g/kgBW (0.56 ml/kgBW) plus ranitidine 30 mg/kgBW right after methanol administration occurred axon degeneration with a statistically significant calculation result when compared to the positive control group not administered ranitidine after administration of methanol. This proves the hypothesis that administration of ranitidine right after administration of methanol may decrease the occurrence of axon degeneration from optic nerve neuropathy due to acute methanol intoxication. In the second treatment group, the group given methanol toxic dose of 14 g/kgBW (0,56 ml/kgBB) plus ranitidine 30 mg/kgBB 30 minutes after methanol administration occurred degeneration of axon with statistical calculation results showed no significant difference when compared with positive control group not given ranitidine after methanol administration. However, based on the histopathologic picture, a normal optical nerve axon is better than the positive control group. This proves the hypothesis that administration of ranitidine 30 minutes after administration of methanol can decrease the occurrence of axon degeneration from optic nerve neuropathy due to acute methanol intoxication. Further research on comparing doses of ranitidine to determine the level of work effectiveness of ranitidine is seen in terms of graded doses of administration in the prevention of methanol metabolism that produces toxic substances that can cause degeneration of the optical nerve axon is very needed.

**Acknowledgement:** The authors wish to thank Dr. Dwi Pudjonarko, MD and Neurology Department of General Hospital Dr. Kariadi, Semarang, Indonesia for any help, permission, cooperation, and good guidance during the research. The author also thank the Animal House of Experimental Research Laboratory, Diponegoro University in providing tools and research materials and Histopathology Laboratory Diponegoro University in histopathology reading and data analysis.

## REFERENCES

- Rietjens SJ, Lange DW De, Meulenbelt J. Ethylene glycol or methanol intoxication: which antidote should be used, fomepizole or ethanol? 2014;(2):73–9.
- Jahan K, Mahmood D, Fahim M. Effects of Methanol in Blood

- Pressure and Heart Rate in the Rat. *J Pharm Bioallied Sci* [Internet]. 2015;7(1):60. Available from: <http://www.jpbonline.org/text.asp?2015/7/1/60/148747>
- Barceloux, DG et al. Methanol Guidelines - AACT/EAPCCT American Academy of Clinical Toxicology Practice Guidelines on the Treatment of Methanol Poisoning. *Journal of Toxicology - Clinical Toxicology*. 2002; 40 (4): 415-446.
- Dorokhov YL, Shindyapina A V., Sheshukova E V., Komarova T V. Metabolic Methanol: Molecular Pathways and Physiological Roles. *Physiol Rev* [Internet]. 2015;95(2):603–44. Available from: <http://physrev.physiology.org/cgi/doi/10.1152/physrev.00034.2014>
- Işcan Y, Coşkun Ç, Öner V, Türkçü FM, Taş M, Alakuş MF. Bilateral Total Optic Atrophy due to Transdermal Methanol Intoxication. *Middle East Afr J Ophthalmol* [Internet]. 2013;20(1):92–4. Available from: <http://www.pubmedcentral.nih.gov/articlerender.fcgi?artid=3617539&tool=pmcentrez&rendertype=abstract>
- Sharma R, Marasini S, Sharma AK, Shrestha JK, Nepal BP. Methanol poisoning: ocular and neurological manifestations. *Optom Vis Sci*. 2012;89(2):178–82.
- Ekka M, Aggarwal P. Toxicology symposia – Review Article Toxic alcohols. 2015;20(1).
- Mégarbane B. Treatment of patients with ethylene glycol or methanol poisoning: Focus on fomepizole. *Open Access Emerg Med*. 2010;2:67–75.
- Halisa S, Prayitnaningsih S, Way O. Perbandingan Efek Ranitidin, Dexametason dan Kombinasinya terhadap Kadar Asam Format Darah dan Pelepasan Sitokrom C Retina pada Model Tikus Intoksikasi Metanol Akut Comparison of Ranitidine, Dexamethasone and Their Combination Effect on Blood Formic Acid. 26(3):171–5.
- El-Bakary A a, El-Dakrory S a, Attalla SM, Hasanein N a, Malek H a. Ranitidine as an alcohol dehydrogenase inhibitor in acute methanol toxicity in rats. *Hum Exp Toxicol*. 2010;29(2):93–101.
- Bestic M, Blackford M, Reed M. Therapeutic review: Fomepizole: A critical assessment of current dosing recommendations. *J Clin Pharmacol*. 2009;49(2):130–7.
- McCoy HG, Cipolle RJ, Ehlers SM, Sawchuk RJ, Zaske DE. Severe methanol poisoning. Application of a pharmacokinetic model for ethanol therapy and hemodialysis. *Am J Med*. 1979;67(5):804–7.
- Hayreh SS. Structure of the Optic Nerve. Springer-Verlag Berlin Heidelberg [Internet]. 2011;7–32. Available from: <http://physrev.physiology.org/cgi/doi/10.1152/physrev.00034.2014>
- Wallage HR, Watterson JH. Formic acid and methanol concentrations in death investigations. *J Anal Toxicol*. 2008;32(3):241–7.
- Hietala J, Vouri A, Johnsson P, Pollari I, Werner R, Kieczka H. Formic Acid. *Ullmann's Encycl Ind Chem*. 2016;(2000):1–23.