

2013_actamedica_Virilization- Leydic_cell_tumour_AZJ_et_al.p df

by Anastasia Ediat

Submission date: 03-Aug-2018 08:54AM (UTC+0700)

Submission ID: 987176498

File name: 2013_actamedica_Virilization-Leydic_cell_tumour_AZJ_et_al.pdf (2.25M)

Word count: 2967

Character count: 16528

Virilization Due to Androgen Hypersecretion in a Patient with Ovarian Leydig Cell Tumor: Diagnostic and Psychosocial Implications

Achmad Z. Juniarto^{1,2}, Bestari A. Setyawati^{2,4}, Annastasia Ediati^{2,3},
Yvonne G. van der Zwan¹, Leendert H.J. Looijenga⁴, Frank H. de Jong⁵,
Arianne Dessens¹, Stenvert L.S. Drop¹, Sultana M.H. Faradz²

¹ Department of Pediatrics, Erasmus University MC-Sophia Children's Hospital, Rotterdam, The Netherlands.

² Department of Human Genetics, Center for Biomedical Research Faculty of Medicine, Diponegoro University (FMDU), Semarang, Indonesia. ³ Faculty of Psychology, Diponegoro University, Semarang, Indonesia.

⁴ Department of Pathology, Erasmus MC - University Medical Center, Josephine Nefkens Institute, Rotterdam, The Netherlands. ⁵ Department of Internal Medicine, Section of Endocrinology, Erasmus University Medical Center Rotterdam, The Netherlands.

Correspondence mail:

Department of Pediatrics, Sophia Children's Hospital, Erasmus MC. PO Box 2060, 3000 CD, Rotterdam, The Netherlands. email: zulfa_juniarto@yahoo.com.

ABSTRAK

Virilisasi akibat kelebihan hormon androgen yang terjadi pada wanita akan menimbulkan tanda-tanda seperti pembesaran klitoris, perubahan suara, tumbuhnya rambut di wajah dan tubuh yang menjadi ciri khas laki-laki. Virilisasi yang disebabkan oleh tumor ovarium tidak lebih dari 0,5% dari seluruh penyebab. Kami melaporkan kasus virilisasi akibat tumor sel Leydig pada ovarium kiri wanita usia 36 tahun. Kesalahan interpretasi, informasi medis yang saling bertentangan dan saran dari dokter sebelumnya membuat kebingungan dari pasien tersebut. Kami melakukan evaluasi diagnostik yang meliputi gambaran klinik, hormon, pencitraan, pemeriksaan patologi, molekuler serta pemeriksaan psikologi.

Pemeriksaan hormon menunjukkan kadar testosteron yang sangat tinggi. Adanya tumor pada ovarium terdeteksi dari pemeriksaan laparoskopi. Biopsi pada ovarium kiri dilakukan oleh karena pasien menolak dilakukan pengangkatan ovarium. Hasil pemeriksaan patologi menunjukkan tumor sel Leydig tanpa adanya tanda keganasan. Pengelolaan menjadi kurang optimal karena faktor sosial budaya yang menghambat walaupun telah dilakukan konseling secara mendalam. Tumor sel Leydig pada ovarium dicurigai apabila terjadi virilisasi pada wanita usia reproduktif disertai peningkatan hormon androgen, massa ovarium pada pemeriksaan pencitraan dan dibuktikan dengan hasil biopsi. Hal ini penting sebelum memberikan saran maupun pengobatan kepada pasien.

Kata kunci: diagnostik work up, virilisasi, sel tumor Leydig.

ABSTRACT

Virilization due to hyperandrogenism in women causes male signs and symptoms such as swelling of the clitoris, deepening of the voice, facial hair and increase in body hair. Virilization is caused by less than 0.5% of all ovarian tumors. Here we report a case of virilizing Leydig cell tumor of the left ovary in a 36 year old woman. Misinterpretation of symptoms, conflicting medical information and advice from previous doctors had confused the patient. We performed a diagnostic evaluation including clinical, hormonal parameters, imaging, anatomical pathology examinations, and psychological assessment.

Blood analysis showed a high testosterone level. The presence of an ovarian tumor was confirmed by laparoscopy. Since the patient refused ovariectomy, a biopsy of the left ovary was performed. Pathology showed a Leydig cell tumor without histological signs of malignancy. In spite of extensive explanation and psychological counseling, cultural barriers prevented appropriate treatment. An ovarian Leydig cell tumor should always be considered for a woman in the reproductive age with symptoms of virilization. The diagnosis is suspected on the basis of an ovarian mass on examination and further investigation and should be proven by biopsy.

Key words: diagnostic work up, virilization, Leydig cell tumor

INTRODUCTION

Androgen excess is the most common endocrine disorder in reproductive-aged women, affecting approximately 7% of this population.¹ This results in ovulatory dysfunction and the development of androgenic features such as hirsutism, androgenic alopecia, acne, and, if extreme and prolonged, virilization of the genitalia.

Hyperandrogenism comprises of a heterogeneous group of disorders that exhibit a common phenotype. The most common causes include polycystic ovary syndrome (PCOS), defects of adrenal or ovarian steroidogenic enzymes, ovarian hyperthecosis, and theca cell hyperplasia. Another reason is the presence of an androgen producing ovarian neoplasm, although these are rare and account for less than 0.5% of all ovarian tumors. These tumors are composed entirely or predominantly of Leydig cells. A previous investigation showed that SRY-independent SOX9 expression can be found in ovarian Sertoli-Leydig cell tumors although the exact mechanisms still remain obscure.² Finally, spontaneous testosterone production might be caused by an activating mutation in the LH receptor (LHR).

Here we report a case of an androgen producing ovarian tumor in an adult woman. In addition, we described the psychosocial and cultural barriers that prevented appropriate treatment.

CASE ILLUSTRATION

History of Patient

A 36-year-old single woman presented at our outpatient clinic with complaints of fatigue, hirsutism and signs of marked virilization (Figure 1). Menarche occurred at the age of 12 and she

had regular cycles until the age of 28. After a period of 5 months of amenorrhea, she visited a gynecologist. Presuming the clinical diagnosis of PCOS, progestagen treatment was prescribed, which induced withdrawal bleedings. Since then, her periods remained under progestagen therapy. She reported that during the following 3 years there she experienced progressive masculinization such as virilization, facial hair growth, deepening of her voice, and a prominent Adam's apple. Her family history was negative for endocrinopathies.

Subsequently, she was referred to our center. Upon physical examination she was 152 cm tall and weighed 56 kg (BMI: 24.2). She had excessive pubic and abdominal hair (Ferriman-Gallwey score 15). A male type beard was present; there was no acne. The breasts were atrophied (Tanner stage 3). The blood pressure varied between 110/70 and 200/110 mm Hg and pulse rate was 80 per minute. External genital examination showed an enlarged clitoris (2.5 cm) and a normal female opening of the urethra, absence of fusion of labia majora and minora (Figure 1).

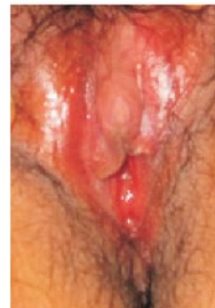

Figure 1. Enlargement clitoris and excessive pubic hair

Hormonal analyses were performed, of which the results are shown in **Table 1**. Pelvic and abdominal ultrasonographic examination showed normal ovaries on both sides and a normal-sized uterus. The adrenal glands and kidneys were also normal.

Table 1. Results of hormonal evaluation of the patient

Hormone*	unit	patient	Reference ranges
			women**
LH	IU/l	12.3	1.5-8.0
FSH	IU/l	8.1	1.0-8.0
Progesterone	nmol/l	2.0	<0.5-3.0
17-hydroxyprogesterone	nmol/l	9.9	<0.5-2.0
Androstenedione	nmol/l	18.0	2.0-10.0
Testosterone	nmol/l	59.5	0.5-3.0
DHEA sulfate	μmol/l	3.8	1.0-10.0
Cortisol	nmol/l	191	200-800
AMH	μg/l	0.9	0.5-7.0

* DHEA: dehydroepiandrosterone; AMH: anti-Müllerian Hormone; LH: Luteinizing Hormone; FSH: Follicle Stimulating Hormone, ** Values during the first week of the menstrual cycle

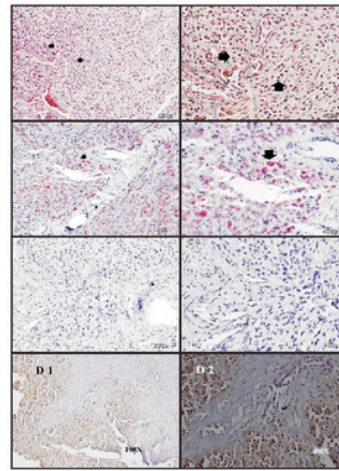


Figure 2. Ovary with a Leydig cell tumor. H&E staining revealed ovarian structures with gonadal stromal tumor compatible with Leydig cells (A1-2) (black arrow). Positive inhibin α -subunit was staining (B1-2); Negative for SOX 9 staining (C1-2). Magnification: left panel x 100, right panel x 400. Luteinizing hormone receptor (LHR) presence was detected by immunohistochemistry. Brown staining in cytoplasm shown in cord-stromal of the ovary. Magnifications were x 100 (D1) and x 400 (D2)

Hormonal results suggested an androgen producing tumor originating from the ovary although this was not confirmed by ultrasound. Therefore, abdominal laparoscopy was undertaken. A biopsy was taken of the left ovary, which contained a structure with the appearance of a polycystic tumor (lesion size 4x3.2x3.4cm). The right ovary did not show macroscopic abnormalities (size:3.3x2.8x1.5 cm).

Histopathological Examination

Histopathological examination demonstrated the presence of an ovarian tumor. The tissue consisted of small epithelioid cells with a pale eosinophilic, well-demarcated cytoplasm and small nuclei with dark chromatin. No atypical cells or mitotic figures were noticed. Reinke crystals were not found in the specimen. The tumor cells stained positive for the inhibin α -subunit and LHR, markers for Leydig cells, and negative for SOX9, a marker for Sertoli cells (**Figure 2**). These findings are consistent with a gonadal stromal tumor, and specifically for a Leydig cell tumor. No histological signs of malignancy were identified. Analysis of the

hot spot region in exon 11 of the LHR gene, mutations of which can lead to constitutive activation of the LHR, did not show a mutation. In conclusion the left ovary contained a gonadal stromal tumor compatible with a Leydig cell tumor lacking histological signs of malignancy.

Luteinizing Hormone Receptor Analysis

Analysis of the hot spot region in exon 11 of the LHR gene, mutations of which can lead to constitutive activation of the LHR, did not show a mutation (**Figure 3**).

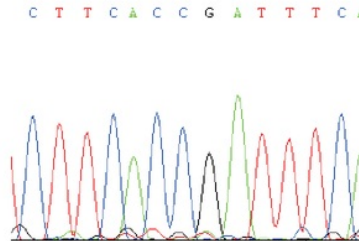


Figure 3. Sequence of luteinizing hormone receptor gene on exon 11 from Leydig cell tumor coding for Phe576, Thr577, Asp578 and Phe 579 showing a wild type receptor.

Psychosocial Aspects

The patient came from a middle class Javanese family and obtained a university degree. The virilization of her body caused her a lot of distress. She consulted several medical doctors and beauticians who gave her conflicting advice. All treatments she underwent had been unsuccessful as she virilized progressively. After we found the cause of her virilization, we informed her about her condition and the nature of the ovarian tumor and proposed ovariectomy. She refused treatment, as she feared to become infertile after treatment. She particularly feared the social consequences of being an infertile woman. As an alternative, hormonal replacement therapy was proposed, but she refused. In the past she had already experienced that progestagen therapy could not stop virilization. One of the doctors she had consulted before had informed her that a pregnancy would cure her disease and she preferred to follow this advice. She kept looking for a partner, but remained unsuccessful. Psychological counselling was offered to allow her to express her worries and to help her understand her condition and its consequences, the necessity for treatment and the rationale behind the proposed treatments. She discussed the pressure she felt to marry and have children. She had already turned 36, whereas most Javanese women will marry and have their first child between age 20 and 30. It was expected that family support could take away some of the experienced shame and distress and proposed to establish such support by informing the family about her condition. However, this was unsuccessful. She told that she had already informed her family and disliked subsequent discussions. No signs of mental disorder and symptoms of depression were present. Her openness to discuss the impact of her condition on her life and her maintained confidence in cure by getting pregnant clarified her resistant attitude.

DISCUSSION

Systematic investigations in adult women with virilization are necessary to establish the right diagnosis. According to the literature, clinical signs of virilization should be confirmed by hormonal and ultrasound examinations.³

Laparoscopy followed by biopsy is necessary to obtain a histopathological description and diagnosis.

In this patient, symptoms of hyperandrogenism were the main initial clinical features. The signs of hirsutism and amenorrhea appeared at the age of 28 years within a 5 month period. Before, she had regular menses and pubertal development had also been normal. Initially a diagnosis of PCOS was considered and indeed hormonal treatment resulted in regular bleedings, which may have convinced the patient that she was fertile. However the progressive virilization even under hormonal treatment had raised suspicion for an androgen-secreting tumor. The hormonal data suggested an androgen-producing tumor of the ovary since serum hormone assay showed increased levels of 17-hydroxyprogesterone and androstenedione and extremely high levels of testosterone with normal levels of the adrenal steroids cortisol, and dehydroepiandrosterone sulfate. Her bodily changes such as signs of virilization, including severe hirsutism, frontal balding, clitoromegaly, increased libido, altered body fat, increased muscle mass, breast atrophy, deepening of voice, and pustular acne were in accordance with hormonal data are common symptoms in Leydig cell ovarian tumors.⁴ Estrogenic manifestations, such as irregular menses have also been reported. Symptoms and signs may present gradually with the onset of symptoms ranging from 5 to 7 years prior the diagnosis.⁵ This patient is exceptionally young as the mean age of women with a Leydig cell tumor is 58 years.⁴

Sex cord-stromal tumors are known as the most common androgen-secreting ovarian tumors, representing less than 0.5% of all ovarian neoplasms. The histological classification of ovarian tumors conducted by the World Health Organization categorize sex cord tumors as granulosa-theca cell stromal tumors, Sertoli-stromal cell tumors, sex cord tumor with annular tubules, gynandroblastoma, unclassified, and steroid cell tumors. About 15% to 20% of steroid cell tumors could be attributed to Leydig cell tumors.

Interestingly whereas Leydig cell tumors are usually benign histo-pathologically, these tumors

can behave in a clinically malignant fashion.⁶ About 20% of patients develop metastatic lesions usually within the peritoneal cavity, and rarely at distant sites.⁷ Therefore, early treatment is necessary to prevent tumor to get worse.

The appearance of a virilizing tumor on radiological imaging depends on the type of tumor. Characteristic of steroid cell tumors are typically small nodules less than 3 cm and unilateral.⁸ These tumors show a heterogeneous solid mass with internal areas of intracellular lipid and may be difficult to identify on radiological imaging, in part because they are isoechoic to the uterus on ultrasound. This may be the reason why no abnormality of the ovaries was found during ultrasound examination of our patient. CT or MRI was not done because of financial limitations.

In view of patient's age and nulliparity, unilateral oophorectomy was offered as the first therapeutic option. Her refusal worsened her medical condition. Her decision to decline the given advice was related to the psychological mechanisms that will be triggered in case the offered cure is not congruent with the patient's beliefs and also includes unfavorable social consequences.^{9,10} For young adult females, loss of fertility involves a social disadvantage. The patient made clear that she considered her ovaries as the only female part of her body that had been left and removal of even one ovary would mean taking away her femininity and everything that made her life worth to live. Her refusal for further discussion about treatment created a dilemma based on the respect for the patient's right on the one hand, but the risk of further progression of the tumor on the other. In spite of efforts for additional appointments to discuss the possibility of ovariectomy, no changes in her opinion occurred. Therefore it is expected that over the years, virilization and weight gain will become more prominent. Androgen excess in women may lead to social withdrawal or even social phobia which will normalize after treatment.^{5,11} However, in our patient, no signs of anxiety or depression were found.

CONCLUSION

This case report confirms that virilization in women should be investigated systematically and

comprehensively. The diagnosis of Leydig cell tumor is made using clinical parameters such as amenorrhea, signs of virilization, and high serum testosterone levels and subsequently the finding of an ovarian mass on imaging. A diagnostic laparoscopy is indicated to confirm the diagnosis. Androgen secreting tumors, especially Leydig cell tumors of the ovary, should be considered among disorders causing virilization in women at reproductive age. What can be learned from this case? Even after comprehensive explanation and psychosocial counseling, cultural barriers prevented appropriate treatment. Social and community support is essential in the management of this patient.

REFERENCES

1. Azziz R, Sanchez LA, Knochenhauer ES, et al. Androgen excess in women: experience with over 1000 consecutive patients. *J Clin Endocrinol Metab.* 2004;89(2):453-62.
2. Kato N, Fukase M, Motoyama T. Expression of a transcription factor, SOX9, in Sertoli-stromal cell tumors of the ovary. *Int J Gynecol Pathol.* 2004;23(2):180-1.
3. Denny MC, Smith D, O'Shea D, McKenna TJ. Investigation of patients with atypical or severe hyperandrogenaemia including androgen-secreting ovarian teratoma. *Eur J Endocrinol.* 2010;162(2):213-20.
4. Gershenson DM, Young RH. Ovarian sex cord-stromal tumors. In: Hoskins WJ, ed. *Principles and practice of gynecologic oncology.* 4th ed. Philadelphia: Lippincott Williams & Wilkins; 2005. p. 1024.
5. Nardo LG, Ray DW, Laing I, Williams C, McVey RJ, Seif MW. Ovarian Leydig cell tumor in a perimenopausal woman with severe hyperandrogenism and virilization. *Gynecol Endocrinol.* 2005;21(4):238-41.
6. Yetkin DO, Demirsoy ET, Kadioglu P. Pure leydig cell tumour of the ovary in a post-menopausal patient with severe hyperandrogenism and erythrocytosis. *Gynecol Endocrinol.* 2011;27(4):237-40.
7. Haji AG, Sharma S, Babu M, Vijaykumar D, Chitrathara K. Androgen secreting steroid cell tumor of the ovary in a young lactating women with acute onset of severe hyperandrogenism: a case report and review of literature. *J Med Case Reports.* 2007;18(1):182.
8. Jung SE, Rha SE, Lee JM, Park SY, Oh SN, Cho KS, Lee EJ, Byun JY, Hahn ST. CT and MRI findings of sex cord-stromal tumor of the ovary. *AJR Am J Roentgenol.* 2005;185(1):207-15. PubMed PMID: 15972425.
9. Situmorang A. Staying single in a married world. *Asian Population Studies.* 2007;3(3):287-304.

10. Albert I, Trommsdorff G, Mayer B, Schwarz B. Value of children in urban and rural Indonesia: socio-demographic indicators, cultural aspects, and empirical findings. In: Trommsdorff G, Nauck B, eds. *The value of children in cross-cultural perspective case studies from eight societies*. Lengerich: Pabst science; 2005. p. 171-207.
11. Ekback M, Wijma K, Benzein E. "It is always on my mind": women's experiences of their bodies when living with hirsutism. *Health Care Women Int*. 2009;30(5):358-72.

ORIGINALITY REPORT

17 %	11 %	14 %	3 %
SIMILARITY INDEX	INTERNET SOURCES	PUBLICATIONS	STUDENT PAPERS

PRIMARY SOURCES

1	www.inaactamedica.org Internet Source	1 %
2	Varras, Michail, Thivi Vasilakaki, Evangelia Skafida, and Chistodoulos Akrivis. "Clinical, ultrasonographic, computed tomography and histopathological manifestations of ovarian steroid cell tumour, not otherwise specified: our experience of a rare case with female virilisation and review of the literature", <i>Gynecological Endocrinology</i> , 2011. Publication	1 %
3	Preetha Nair. "Hirsutism in a Fifty-Eight-Year-Old Woman", <i>The Endocrinologist</i> , 09/2008 Publication	1 %
4	www.thieme-connect.de Internet Source	1 %
5	Inessa M. Gelfand. "Gonadal and Adrenal Tumors", <i>Contemporary Endocrinology</i> , 2007 Publication	1 %

6

Gulsum Uysal, Yilmaz Sahin, Kursad Unluhizarci, Ayten Ferahbas, Semih Zeki Uludag, Ercan Aygen, Fahrettin Kelestimur. "Is acne a sign of androgen excess disorder or not?", *European Journal of Obstetrics & Gynecology and Reproductive Biology*, 2017

Publication

1%

7

cjasn.asnjournals.org

Internet Source

1%

8

Kristel Goossens. "Lack of correlation between phenotype and genotype in untreated 21-hydroxylase-deficient Indonesian patients", *Clinical Endocrinology*, 11/2009

Publication

1%

9

ww.turner-white.com

Internet Source

1%

10

revistasochog.cl

Internet Source

1%

11

Kanchan Murhekar. "A rare occurrence of a steroid cell tumor of the pelvic mesentery: a case report", *Journal of Medical Case Reports*, 2011

Publication

1%

12

doaj.org

Internet Source

1%

13	Yildiz, B.O.. "Diagnosis of hyperandrogenism: clinical criteria", Best Practice & Research Clinical Endocrinology & Metabolism, 200606 Publication	<1%
14	www.ajronline.org Internet Source	<1%
15	dissertations.ub.rug.nl Internet Source	<1%
16	Sanchez, L.A.. "Determining the time androgens and sex hormone-binding globulin take to return to baseline after discontinuation of oral contraceptives in women with polycystic ovary syndrome: a prospective study", Fertility and Sterility, 200703 Publication	<1%
17	elsevier.pt Internet Source	<1%
18	pagepress.org Internet Source	<1%
19	ard.bmj.com Internet Source	<1%
20	www.omicsonline.org Internet Source	<1%
21	Blaustein's Pathology of the Female Genital Tract, 2011.	<1%

22

Endocrine Pathology, 2004.

Publication

<1%

23

Winarni, T I, F E P Mundhofir, A Ediati, M Belladona, W M Nillesen, H G Yntema, B C J Hamel, S M H Faradz, and R J Hagerman. "The fragile X-associated tremor ataxia syndrome (FXTAS) in Indonesia : FXTAS in Indonesia", Clinical Genetics, 2013.

Publication

<1%

24

preview-gynecolsurg.springeropen.com

Internet Source

<1%

25

Lawrence M. Roth. "Recent Advances in the Pathology and Classification of Ovarian Sex Cord-Stromal Tumors", International Journal of Gynecological Pathology, 07/2006

Publication

<1%

26

Blaustein's Pathology of the Female Genital Tract, 1994.

Publication

<1%

27

Essah, P.A.. "Dermatology of androgen-related disorders", Clinics in Dermatology, 200607/08

Publication

<1%

28

Ozgun, M.T.. "Selective ovarian vein sampling can be crucial to localize a Leydig cell tumor: An unusual case in a postmenopausal woman",

<1%

29 Nardo, L. G., D. W. Ray, I. Laing, C. Williams, R. J. Mcvey, and M. W. Seif. "Ovarian Leydig cell tumor in a peri-menopausal woman with severe hyperandrogenism and virilization", *Gynecological Endocrinology*, 2005. <1%

Publication

30 MICHAEL JOHNSTONE. "THE ROLE OF HALOTHANE IN THE PREVENTION OF SURGICAL SHOCK", *BJA British Journal of Anaesthesia*, 1958 <1%

Publication

31 preview-ovarianresearch.biomedcentral.com <1%

Internet Source

32 "Selected aspects of ovarian pathology", *Pathology International*, 10/2004 <1%

Publication

33 HORTA, Mariana and CUNHA, Teresa Margarida. "Sex cord-stromal tumors of the ovary: a comprehensive review and update for radiologists", *Türk Radyoloji Derneği*, 2015. <1%

Publication

34 Böttcher, Bettina, Bernd Hinney, Johanna Keyser, Ingrid Kühnle, Stefan Schweyer, and Günter Emons. "Sertoli-Leydig cell tumour in a 13-year-old girl", *Gynecological Endocrinology*, <1%

2011.

Publication

35

Ediati, Annastasia Juniarto, Birnie, Erw. "Body Image and Sexuality in Indonesian Adults with a Disorder of Sex Development (DSD).(Report) (Auth", The Journal of Sex Research, Jan 2015 Issue

Publication

<1%

36

Submitted to Miami Dade College

Student Paper

<1%

Exclude quotes On

Exclude matches Off

Exclude bibliography On

2013_actamedica_Virilization-
Leydic_cell_tumour_AZJ_et_al.pdf

GRADEMARK REPORT

FINAL GRADE

/18

GENERAL COMMENTS

Instructor

PAGE 1

PAGE 2

PAGE 3

PAGE 4

PAGE 5

PAGE 6
